

is broader and blunter; and in the specimen, fig. 8, it is so in a remarkable degree. This point approaches nearer to the auditory meatus than in the wild rabbit, as may be best seen in fig. 8; but this circumstance mainly depends on the changed direction of the

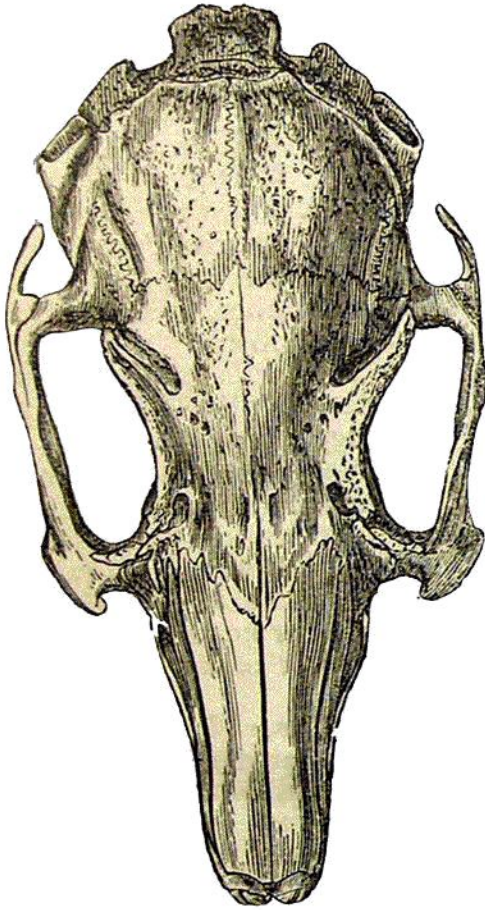


Fig. 6.—Skull of Wild Rabbit, of natural size.

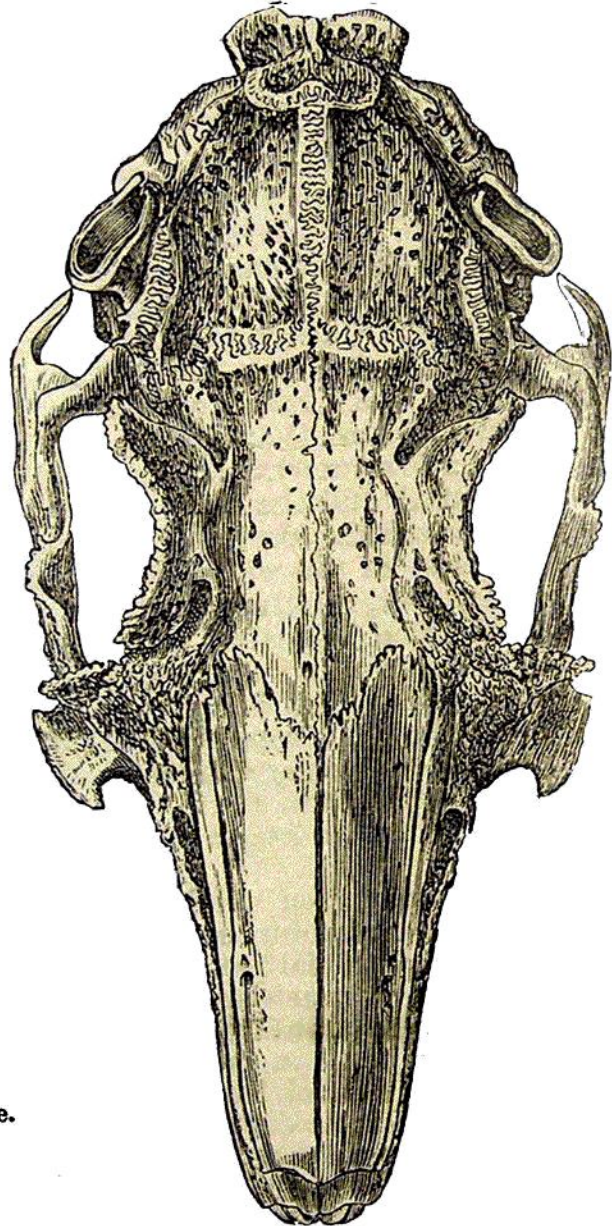


Fig. 7.—Skull of large Lop-eared Rabbit, of natural size.

meatus. The inter-parietal bone (see fig. 9) differs much in shape in the several skulls; generally it is more oval, that is more extended in the line of the longitudinal axis of the skull, than in the wild rabbit. The posterior margin of "the square raised plat-