

Fig. 54

Upper surface of brain of Chimpanzee, distorted (from Schroeder van der Kolk and Vrolik).
 A. Left cerebral hemisphere.
 B. Right ditto.
 c. Cerebellum displaced.

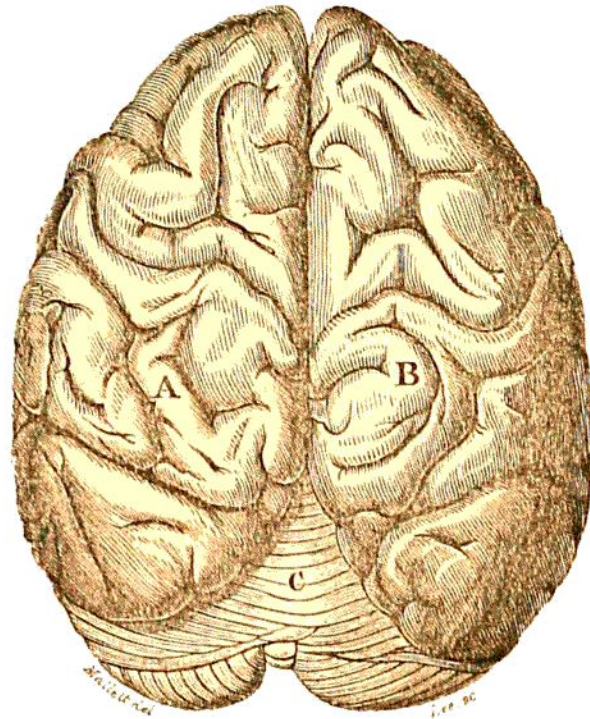


Fig. 55

Side view of same (from Schroeder van der Kolk and Vrolik), showing at *e* the extension of the displaced cerebellum beyond the cerebrum at *d*.



Fig. 56

Correct side view of Chimpanzee's brain (from Gratiolet), showing the backward extension of the cerebrum at *d*, beyond the cerebellum at *e*.
f f. Fissure of Sylvius.

