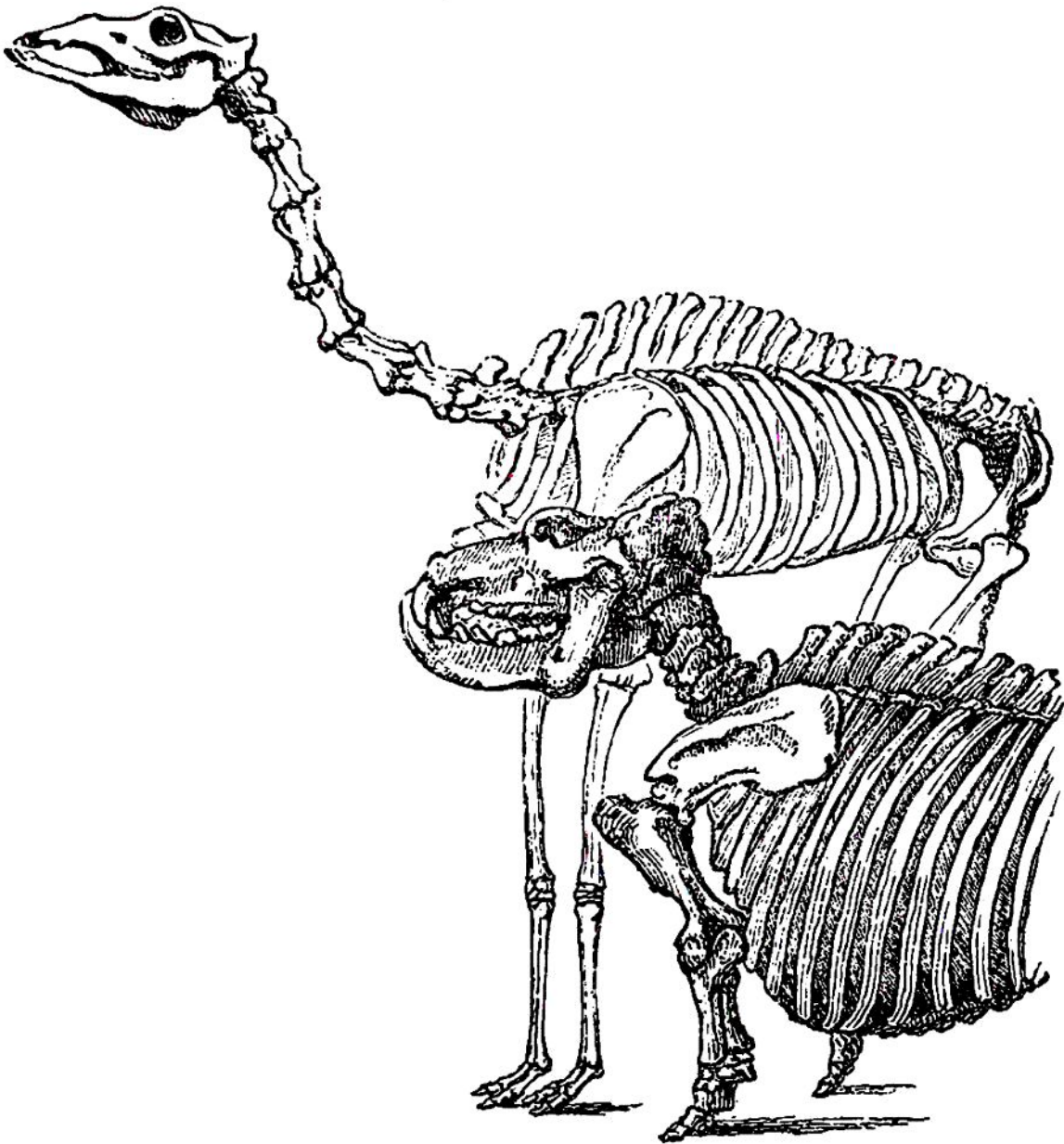


and that the motions of respiration belong more to the posterior ribs.* Although in this creature



there seems to be a due proportion between the

* We have here a sketch of the skeletons of the hippopotamus and of the camel, as they stood accidentally contrasted. The head of the hippopotamus is of great strength and weight, and it is appended to a short neck ; in the shortness of the legs also we see the correspondence that we have had occasion to remark between the position of the head and the height of the trunk from the ground. The camel is, in every respect, a contrast. It must